

RESEARCH

Open Access



Characteristics of retinal image associated with premature ovarian insufficiency: a case-control study

Jiaman Wu^{1†}, Liya Tan^{2†}, Yan Ning¹, Wei-qu Yuan³, Zuowei Lee^{4,5}, Fei Ma¹, Erfeng Wang² and Yuanyuan Zhuo^{3*}

Abstract

Purpose To establish an early clinical diagnosis model based on the retinal vascular features associated with POI, supplying a non-invasive way for accurately and early predicted the risk of POI.

Methods A total of 78 women with spontaneous POI and 48 healthy women were recruited from the Affiliated Shenzhen Maternity & Child Healthcare Hospital in the study. Retinal characteristics were analyzed using an automated retinal image analysis system. Binary logistic regression was used to identify POI cases and develop predictive models.

Results Compared to the normal group, the POI group had larger central retinal artery equivalent (CRAE) ($P=0.006$), central retinal vein equivalent (CRVE) ($P=0.001$), index of venules asymmetry (Vasym) ($P=0.000$); larger bifurcation angles of arterioles (Aangle) ($P=0.001$), bifurcation coefficient of venule (BCV) ($P=0.001$) and more obvious arterio-venous nipping (Nipping) ($P=0.005$), but lower arteriole-to-venule ratio (AVR) ($P=0.012$). In the POI group, the odds ratio (OR) of Vasym was $6.72e-32$ (95% C.I. $4.62e-49-9.79e-15$, $P=0.000$), the OR of BCV was $5.66e-20$ (95% C.I. $1.93e-34-0.000$, $P=5.66e-20$) and the OR of Nipping was $6.65e-06$ (95% C.I. $6.33e-10-0.0698$, $P=0.012$). Moreover, the area under the ROC curve for the binary logistic regression with retinal characteristics was 0.8582, and the fitting degree of regression models was 60.48% (Prob > chi-square = 0.6048).

Conclusion This study demonstrated that retinal image analysis can provide useful information for POI identification and certain characteristics may help with early clinical diagnosis of POI.

Keywords Retinal characteristics, Premature ovarian insufficiency, Retinal image analysis, Biostatistics method, Early clinical diagnosis

[†]Jiaman Wu and Liya Tan contributed equally to this paper.

*Correspondence:

Yuanyuan Zhuo

qinyuan64@163.com

¹ Affiliated Shenzhen Maternity & Child Healthcare Hospital, Southern Medical University, Shenzhen 518028, China

² Guangzhou University of Chinese Medicine, Guangzhou, China

³ Shenzhen Traditional Chinese Medicine Hospital, Shenzhen 518033, China

⁴ Division of Biostatistics, Jockey Club School of Public Health and Primary Care, The Chinese University of Hong Kong, Hong Kong, China

⁵ Centre for Clinical Trials and Biostatistics Lab, CUHK Shenzhen Research Institute, Shenzhen, China

Introduction

Premature ovarian insufficiency (POI) is a clinical syndrome characterized by premature decline of ovarian function, abnormal menstruation (frequent or infrequent menstrual cycles, hypomenorrhea or amenorrhea) [1], increased serum gonadotropin levels and decreased estrogen levels, resulting in the decrease of reproductive function [2]. Currently, the diagnosis of POI is mainly based on clinical symptoms and serum measurements. If a woman under the age of 40 experiences the above symptoms for three consecutive months and has a persistently elevated FSH level above 25mIU/mL, the preliminary diagnosis of POI can be made. However, two



or more blood tests with an interval of 4–6 weeks are required for confirmation, which can be relatively expensive [3, 4]. In addition, there are other diagnostic methods such as ultrasound examination, ovarian stimulation test, genetic testing, etc., that can be used as adjuncts to diagnosis [2]. The prevalence rate of POI in the general population was about 1% [5], and it is not rare among women of childbearing age. A recent national registry study involving 103,6918 women from Sweden showed that the overall prevalence of POI was 1.9% [6].

POI not only affects menstruation and fertility, but also leads to early menopausal symptoms and increased risk of long-term cardiovascular disease [7]. A study [8] in Korea demonstrated that the menstrual cycles of patients with premature ovarian failure (POF) may be affected by the frequencies of vascular endothelial growth factor (VEGF). It was reported that decrease in level of endogenous estrogen can lead to vascular aging, including endothelial cell damage, intimal smooth muscle cell proliferation and other symptoms affecting atherosclerosis formation [9, 10]. Therefore, POI may associate with some vessel's diseases or lead to vascular changes.

The clinical diagnostic of POI is mainly based on clinical symptoms and serum measurements [2]. However, drawing blood for serological examination is invasive. Besides, two or more blood tests with an interval of 4–6 weeks is needed for diagnosis, resulting in a relatively high cost.

Retinal images can reflect the state of micro vessels and provide a direct observation of the changes in fundus vessels. Previous studies found a correlation between changes in fundus vessels and cardiovascular diseases [11–13]. The changes of vessels in POI patients maybe reflect in their retinal characteristics. The retinal image analysis could provide some helpful information for diagnosis of POI by monitoring how healthy their blood vessels are.

Material and methods

Ethical statement

This study was approved by the ethics committee of the Affiliated Shenzhen Maternity & Child Healthcare Hospital (Approval Number: SFYLS2020-012) and was performed in accordance with the guidelines of the Declaration of Helsinki (1964). This study was registered at Chinese Clinical Trial Registry (Registration No. ChiCTR2000029576).

Data collection

In this case–control study, 78 women with spontaneous POI and 48 normal women were recruited from the Affiliated Shenzhen Maternity & Child Healthcare Hospital from August 1st, 2018 to October 30th, 2020.

The average period of amenorrhea was 1.8 years (from 5 months to 4 years) in women with POI. Spontaneous POI was diagnosed according to the criteria established in the management guidelines of the European Society of Human Reproduction and Embryology: primary or secondary amenorrhea lasting for at least 4 months before 40 years old, with at least two measurements of serum follicle-stimulating hormone levels exceeding 25 IU/L with an interval of 4–6 weeks [4, 5]. Patients with karyotype abnormalities, genetic defects (such as Turner syndrome), hypothalamic amenorrhea, POI with autoimmune symptoms, infectious or iatrogenic etiologies or abnormal liver function were excluded. In order to exclude the cardiovascular disease which may influence the retinal vessel, patients with diabetes, hypertension, dyslipidemia, inflammatory disorders were also excluded in this study. 48 normal group with regular menstrual cycles and without POI diagnosis history and cardiovascular diseases was selected (Fig. 1). All participants provided written consent for their participation in the study. The age, height, weight, infertility duration of both the POI group and control group were recorded. The body mass index (BMI) was calculated. The level of follicle-stimulating hormone (FSH), level of luteinizing hormone (LH) and level of estradiol (E2) and level of anti-Mullerian hormone (AMH) of all participants were measured. The FSH/LH ratio was calculated (Table 1).

Sample size

The diagnostic value of ARIA was evaluated by selecting POI patients and normal women. ARIA is expected to diagnose POI with $\alpha=0.025$, power $1-\beta=0.9$, $AUC_0=0.5$, $AUC_1=0.7$. Patients and normal women were estimated with a 1:1 sample size. By using the PASS 15 software, 41 patients and 41 normal women were required to be included, with a total of 82 subjects. To estimate a 10% loss to follow-up, 46 patients and 46 normal women would need to be enrolled. But in our study, 78 POI patients meeting the inclusion criteria were all included.

Retinal characteristics

Retinal images were taken by a digital retinal camera (CR-2 AF, Canon, Japan). To ensure the compatibility of image parameters, retinal images were scaled to $1365 * 1024$ pixels and saved in jpg format. A fully automatic retinal image analysis (ARIA) system [14] using R and MATLAB was used to measure retinal characteristics. Retinal characteristics of retinal vessel in this study are arteriole-venous nipping (Nipping), arteriole occlusion (Aocclusion), tortuosity (Tortuosity), hemorrhages (Hemorrhage), exudates (Exudates), asymmetry index of arterioles (Aasym), bifurcation coefficient of venule

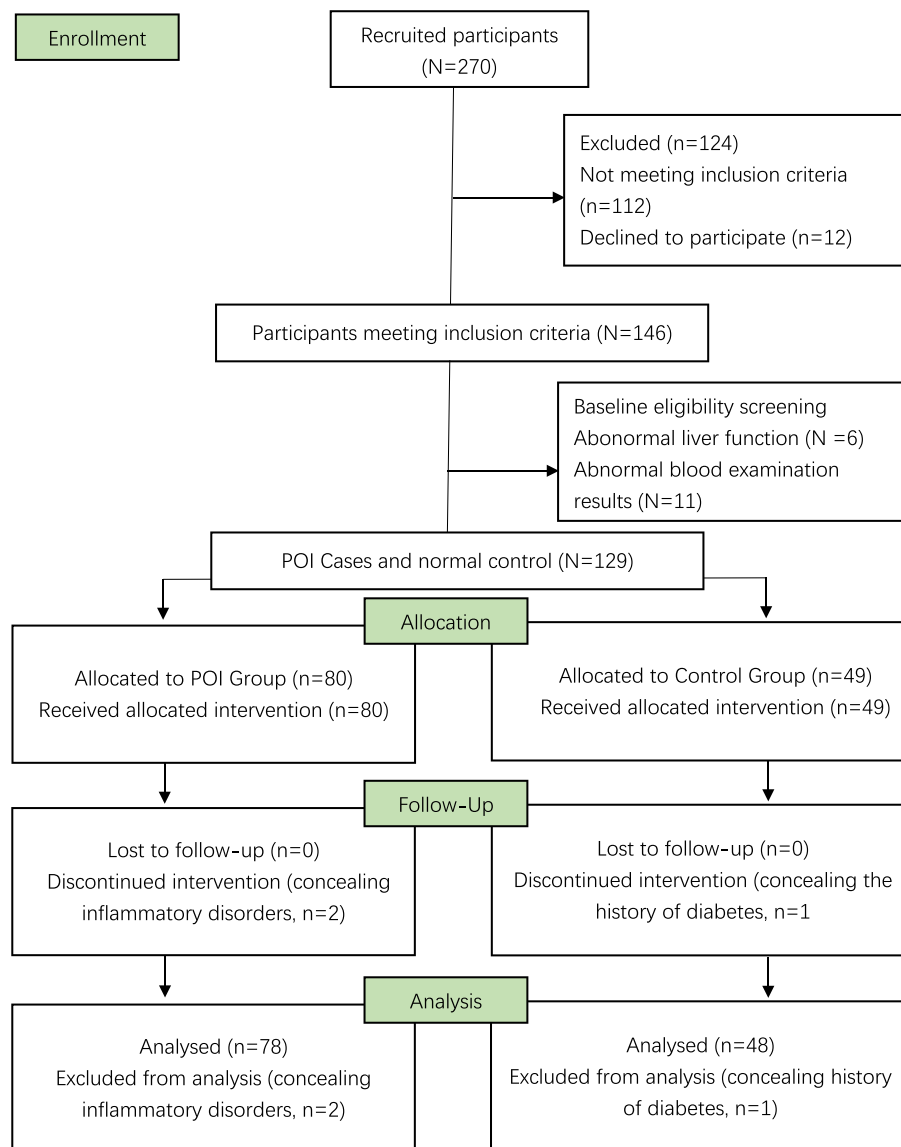


Fig. 1 Flowchart of participant recruitment. POI represents women with premature ovarian insufficiency

(BCV), bifurcation coefficient of arterioles (BCA), and bifurcation angles of venule (Vangle). According to a method developed by Knudtson et al., the retinal vessel measurements were summarized as central retinal artery equivalent (CRAE) and central retinal vein equivalent (CRVE), representing the diameters of arterioles and venules, respectively [15]. The arteriole-to-venule ratio (AVR) was calculated as the ratio of CRAE to CRVE. Vessel tortuosity provides both qualitative and quantitative information by visual grading of one fovea-center and one disc-centered fundus image. Arteriole venous nipping causes narrowing of the venule when crossed by an arteriole. The arteriole occlusions

refer to the blockage of blood flow inside the arterioles when obstructed by an emboli. The branching pattern of retinal vessels, such as BCV, the ratio of the widths of branching vessels to trunk vessels, the angle between two branching vessels and index of venules asymmetry (Vasym), the ratio of diameters of two branching vessels represents the relationship between the trunk and the branching vessels. The fractal dimension of the retinal vasculature (FDv) and arterioles (FDa) measured the complexity of branching patterns. The bifurcation angles of arterioles (Aangle) represent the mean of three sets of vessels in one retinal image. The analysis was performed using three sets of vessels in a single

Table 1 Characterization of POI group and control group

Characteristics	POI Group (n = 78)	Control Group (n = 48)	P-value
Age (year)	34.397 ± 4.04	34.75 ± 4.17	0.640
Height (cm)	160.769 ± 4.43	160.708 ± 5.11	0.944
Weight (kg)	56.583 ± 4.89	56.563 ± 4.839	0.994
Body mass index (kg/m ²)	21.864 ± 1.26	21.880 ± 1.126	0.943
Infertility duration (year)	2.20 ± 1.43	0.25 ± 0.67	0.000
FSH (IU/L)	29.362 ± 7.758	7.590 ± 5.707	0.000
LH (IU/L)	12.491 ± 3.051	6.027 ± 1.735	0.000
FSH/LH ratio	2.345 ± 0.376	1.168 ± 0.351	0.000
E2 (pg/ml)	31.846 ± 10.781	43.625 ± 6.111	0.000
AMH (ng/mL)	0.5687 ± 0.400	2.237 ± 0.756	0.000

POI Premature ovarian insufficiency, BMI Body mass index, FSH Follicle-stimulating hormone, LH Luteinizing hormone, E2 oestradiol, P Progesterone, T Testosterone, PRL Prolactin, AMH Anti-Müllerian hormone

retinal image. Hemorrhage and Exudates were recorded as present or absent and their probabilities (0 to 1) were calculated (Fig. 2).

Statistical analysis

Chi-square tests, and two-tailed independent samples t-tests were used to compare the demographics

and retinal characteristics between the POI group and the control group. Retinal characteristics of patients with POI were identified using a univariate analysis. A p-value < 0.05 was considered as statistically significant. The binary logistic regression with backward stepwise selection was used to select the best model. The classification accuracy and the area under the curve of the

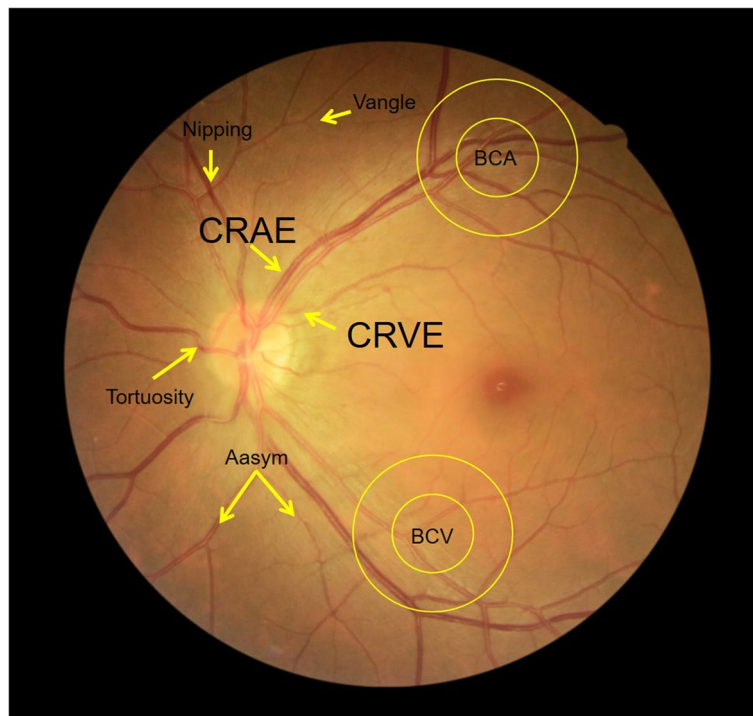


Fig. 2 Characterization of retinal vessel in the POI and control groups. Nipping, arteriole-venous nipping; Aocclusion, arteriole occlusion; Tortuosity, tortuosity; Hemorrhage, hemorrhages; Exudates, exudates; Aasym, asymmetry index of arterioles; Vasym, asymmetry index of venules; BCV, bifurcation coefficient of venule; BCA, bifurcation coefficient of arterioles; Vangle, bifurcation angles of venule; Angle, bifurcation angles of arterioles; CRAE, central retinal artery equivalent; CRVE, central retinal vein equivalent. AVR, CRAE to CRVE ratio; FDv, the fractal dimension of the retinal vasculature; arterioles FDa, the fractal dimension of the retinal arterioles

receiver operating characteristic (ROC) were measured. All the data were analyzed using the Statistical Package for Social Science software Stata 15.0 (Stata Corp., College Station, TX, USA).

Results

The general characteristics of the study participants were summarized in Table 1. The average age was 34.53(SD:±4.11) years, the average BMI was 21.8(SD:±1.13). In the univariate analysis, clinical characteristics such as age, height, weight, BMI showed no statistical significance between the two groups($P>0.05$). Compared to the control group, the POI group had significantly higher average infertility duration (2.20 ± 1.43 V.S. 0.25 ± 0.67 ; $P<0.001$), FSH(29.36 ± 7.76 V.S. 7.59 ± 5.71 ; $P<0.001$), LH(12.49 ± 3.05 V.S. 6.03 ± 1.74 ; $P<0.001$) and FSH/LH ratio (2.35 ± 0.38 V.S. 1.17 ± 0.35 ; $P<0.001$). There were significantly lower levels of average E2 in the POI group (31.85 ± 10.78 V.S. 43.63 ± 6.11 ; $P<0.001$) and AMH

(0.57 ± 0.40 V.S. 2.24 ± 0.76 ; $P<0.001$) than those in the control group.

Compared to the retinal characteristics, the POI group had higher CRAE (13.46 ± 0.44 V.S. 13.22 ± 0.50 ; $P=0.006$), CRVE (20.19 ± 0.44 V.S. 20.01 ± 0.61 $P=0.001$); larger Aangle (72.37 ± 1.32 V.S. 71.56 ± 1.34 , $P=0.001$) and BCV (1.29 ± 0.02 V.S. 1.28 ± 0.02 , $P=0.001$); more obvious Nipping (0.33 ± 0.05 V.S. 0.30 ± 0.06 , $P=0.005$), and lower AVR (0.66 ± 0.03 V.S. 0.67 ± 0.02 , $P=0.012$) (Fig. 3).

The multivariate logistic regression model was built for POI identification. In the POI group, the OR of Vasym was $6.72e-32$ (95% C.I. $4.62e-49-9.79e-15$, $P=0.000$), the OR of BCV was $5.66e-20$ (95% C.I. $1.93e-34-0.0000$, $P=5.66e-20$) and the OR of Nipping was $6.65e-06$ (95% C.I. $6.33e-10-0.0698$, $P=0.012$) (Table 2). Diagnostic testing was performed to evaluate the prediction accuracy of the model. The area under the ROC curve for the binary logistic regression with retinal characteristics was 0.8582, and the goodness of fit test was 60.48% (Prob=0.6048, Prob>chi-square) (Fig. 4).

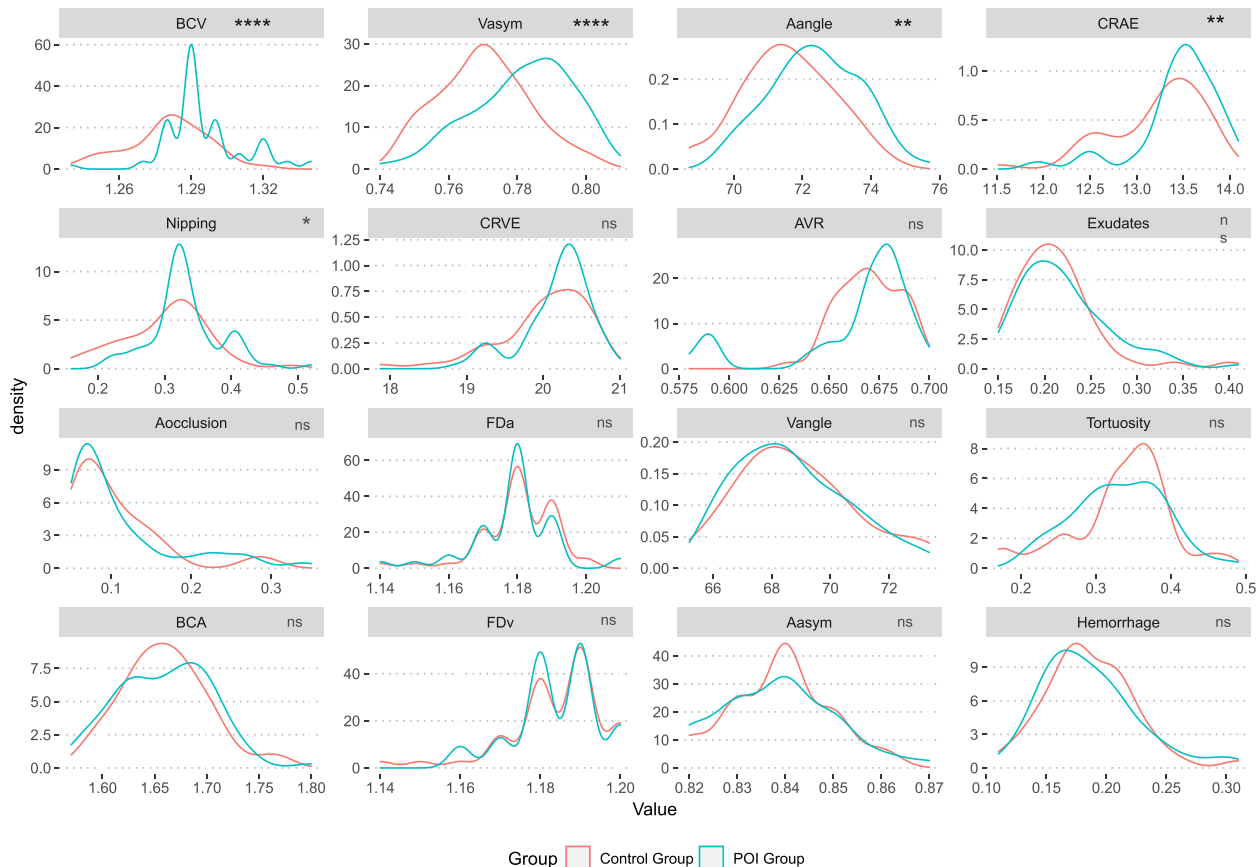


Fig. 3 The retinal characteristics of the POI group and control group. Note: The p -value with a * represents nonparametric test of matched pair data (Wilcoxon Signed-Rank Test), others use paired t-test. **** represents $P < 0.000$, ** represents $P < 0.01$, * represents $P < 0.05$. The retinal characteristics that differed significantly between the POI and control groups. POI represents women with premature ovarian insufficiency

Table 2 Results of the binary logistic regression

Group	Odds Ratio	Std. Err	z	P-value	[95% Conf. Interval]	
CRAE	0.3892482	0.2159073	-1.70	0.089	1.312454	1.154434
Vasym	6.72e-32	1.36e-30	-3.56	0.000*	4.62e-49	9.79e-15
Aangle	0.7426158	0.1383556	-1.60	0.110	0.110	0.5154401
BCV	5.66e-20	9.61e-19	-2.61	0.009*	1.93e-34	0.000166
Nipping	6.65e-06	0.000314	-2.52	0.012*	6.33e-10	0.697619
_cons	1.37e+65	4.00e+66	5.14	0.000*	2.03e+40	9.23e+89

The p-value with a * represents nonparametric test of matched pair data (Wilcoxon Signed-Rank Test), others use paired t-test

Nipping Arteriole-venous nipping, *Aocclusion* Arteriole occlusion, *Tortuosity* Tortuosity, *Aasym* Asymmetry index of arterioles, *Vasym* Asymmetry index of venules, *BCV* Bifurcation coefficient of venule, *BCA* Bifurcation coefficient of arterioles, *Vangle* Bifurcation angles of venule, *Aangle* Bifurcation angles of arterioles, *CRAE* Central retinal artery equivalent, *CRVE* Central retinal vein equivalent, *AVR* CRAE to CRVE ratio, *FDv* The fractal dimension of the retinal vasculature, *arterioles FDa* The fractal dimension of the retinal arterioles

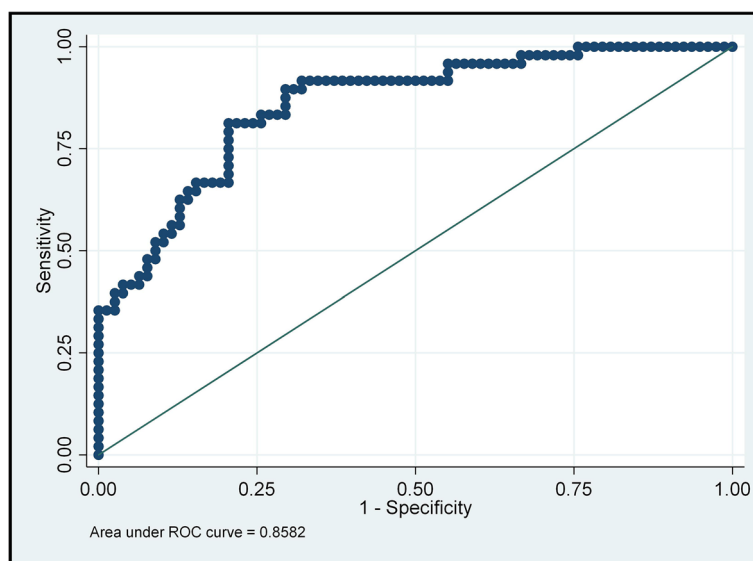


Fig. 4 ROC curve for model classification. Note: Area under ROC curve = 0.8582, Prob > chi2 = 0.6048. The area under the ROC curve for the binary logistic regression with retinal characteristics, and the fitting degree of regression models was 60.48% (Prob > chi-square = 0.6048)

Discussion

Luteinizing hormone, follicle-stimulating hormone and estradiol are the common markers in POI patients. POI indicates an early menopause and it can be diagnosed when the levels of blood LH and FSH increase substantially. One of the most sensitive hormones to diagnosis POI is FSH, which negatively correlated with ovarian function. Therefore, monitoring of elevated FSH for several months is helpful for women to be diagnosed of early-onset ovarian insufficiency. The ovaries occasionally experience a stage of low activity, and then return to normal function. For this reason, to diagnosis POI, at least two hormone measurements from two menstrual cycles are required. Furthermore, time limit to blood test is important, considering that the FSH and LH levels in women vary greatly in each menstrual

cycle, requiring blood samples to be drawn within 3–5 days after menstruation. In a word, the diagnosis using blood examinations is invasive and inconvenient. It is very important to propose an effective, noninvasive diagnostic method for patients with POI in clinical application.

POI not only causes menstrual changes, but also affects blood vessels. E2 has a direct stimulatory effect on vascular endothelial cells via the estrogen receptor [16, 17]. It was reported that the endocrine changes in female patients, especially the decrease of E2, were associated some abnormalities of the microvascular system [18]. Retina is a small part of the vascular system in human body which can be observed directly. It is not only an important sign of retinopathy, but also a direct evidence of vessels injury in human body. Some endocrine diseases, induced by hormone changes,

can affect the vascular system, and can be reflected in the fundus blood vessels. Raizada [19] found that the change in sex hormones can cause the retinal capillaries, arterioles and venules to develop mild per phlebitis. E2 have been linked with alterations in the ocular and retinal circulation, Estrogen-replacement therapy in postmenopausal women can substantially reduce vascular resistance distal of the ophthalmic artery to levels matching those of young women [20]. LH plays a physiologic role in VEGF regulation and retinal vascularization in the development of eyes but it is not required for the development of various components of retina in mouse [21]. In the vasculature of nonmalignant tissues, FSHR is only expressed in placental endothelial cells [22] and to a lesser extent, in the endothelium of ovaries [23] and testis [24]. Estrogen has dual effects on the inflammatory system, with anti-inflammatory and pro-inflammatory effects, which increase after menopause [25, 26]. Inflammatory aging plays an important role in the pathogenesis of POI, leading to the imbalance of inflammatory cytokine network [27], so it can be inferred that POI has a close relationship with vascular endothelial dysfunction and vascular inflammation due to low estrogen level, and this result can be confirmed that there is no sign of accelerated vascular aging in POI women receiving timely and sufficient HRT. Therefore, endothelial function is a barometer of vascular health and a predictor of atherosclerosis, which may begin earlier than usual in female patients with POI [28, 29]. Kalantaridou et al. [30] found that after receiving HRT 6 months, the blood flow mediated diastolic function in POI patients increased more than twice and returned to the normal value similar to that in the control group. It can be inferred that the vascular endothelial function can be effectively reflected by the vascular diastolic function. In our study, we found that POI is related to the increase of risk factors or markers reflecting vasodilation function in retinal fundus vascular analysis, such as Vasym, BCV and Nipping, which is consistent with the author's purpose to distinguish POI from healthy people by observing retinal fundus vessels.

Ocular blood flow velocity was positively correlated with levels of LH, FSH and total cholesterol. Therefore, the characteristics of retinal image can provide useful information for the diagnosis of POI. In our study, we found that the characteristics of retinal image of POI were mainly focus on the vein vessels. The increased branching coefficients of arteries and venules were associated with a higher risk of POI, indicating changes in retinal vascular branching patterns. In healthy individuals, retinal vessels provide optimal pathways for blood flow, and thus the energy consumption is minimal. Therefore,

we hypothesized that the retinal microcirculation abnormalities in POI patients were associated with chronic and lower levels of E2.

So far, there was no literature supporting the finding that the protective effect of estrogen on cardiovascular system is mainly through the influence of coagulation and fibrinolysis system, inflammatory factors and vascular endothelial cells [19, 31–33], which may reflect that microvascular injury is caused by POI and can be identified by retinal bifurcation coefficient. In previous studies, it was denoted that early menopause age is associated with higher CVD risk and POI patients have higher CVD risk and CVD mortality compared to the general population [34–36]. Detection of subclinical atherosclerosis may be an important approach in the prevention of cardiovascular events in these young women with POI. Recent studies have shown that the pathogenesis of early-onset atherosclerosis in ovarian lesions (ovarian aging related diseases, such as POI) is related to ROS induced DNA changes, mitochondrial dysfunction and reduced ATP production. Oxidative stress is the focus of this study, which also suggests the correlation between women with POI and subclinical atherosclerosis. Fundus vessels can reflect systemic vascular conditions, including subclinical arteriosclerosis [37]. The study found POF patients exhibited significantly different frequencies of the VEGF genotype [8], it may influence the level and types of VEGF to affect angiogenesis and angiogenesis of blood vessels. Since biological effects are considered to be more complex, we explored the interaction between retinal features. This study found that the risk of POI increased as the levels of a series of retinal components (CRAE, CRVE, BCA, venous angle, arterial angle, FDA) increased.

Limitation

This study has some limitations. All participants in the study were recruited from the same hospital, which may lead to potential selection bias. Therefore, multicenter clinical studies are necessary in further research. In addition, cross-sectional design resulted in difficulties in causal inference. A larger sample size is needed in further research.

Conclusion

The retinal imaging can provide valuable diagnostic information for patients with POI. Our study has shown that women with POI have special retinal features such as wider retinal arterioles and venules, and had larger bifurcation angles of arterioles. These changes are thought to be related to alterations in the hormonal environment that occur with POI. However, the changes observed in the retinal vessels and other retinal structures can be

non-specific, it may be present in other conditions, such as hypertension and diabetes. The aims of our study were to demonstrate that retinal image analysis can provide useful information for POI identification and certain characteristics may help with early clinical diagnosis of POI. It is important to comprehensively consider other clinical factors, such as age of onset of menopause symptoms, family history, and laboratory testing, to arrive at a definitive diagnosis of POI.

Supplementary materials

These are the retinal images of 126 participants recruited in the study. Supplementary for univariate analysis.

Authors' contribution

J.M. Wu and L.Y. Tan contributed equally to this paper. J. M. Wu and Y.Y. Zhuo conceived of the presented idea and planned the experiments. Y. Y. Zhuo and E. F. Wang conducted the experiments. Z. W. Li, Y. Ning and F. Ma designed the computational framework and analyzed the data. J. M. Wu, L. Y. Tan and Y. Y. Zhuo wrote the manuscript. All authors discussed the results and contributed to the final manuscript.

Availability of data and materials

The EXCEL data used to support the findings of this study are available from the corresponding author upon request.

Declarations

Ethics approval and consent to participate

This study was approved by the Ethics Committee of the Maternity & Child Healthcare Hospital, Southern Medical University and carried out in accordance with the guidelines of the Declaration of Helsinki (Approval number: SFYLS2020-012).

Consent for publication

All patients provided written informed consent prior to participation in any study-related procedures.

Competing interest

The authors declare no competing interests.

Received: 24 January 2022 Accepted: 7 July 2023

Published online: 24 July 2023

References

- Rebar RW, Keator CS. Expanding our knowledge of premature ovarian insufficiency. *Fertil Steril*. 2021;115(2):328–9. <https://doi.org/10.1016/j.fertnstert.2020.09.145>.
- Chae-Kim JJ, Gavrilova-Jordan L. Premature Ovarian Insufficiency: Procreative Management and Preventive Strategies. *Biomedicines* 2018; 7(1)<https://doi.org/10.3390/biomedicines7010002>.
- Sullivan SD, Sarrel PM, Nelson LM. Hormone replacement therapy in young women with primary ovarian insufficiency and early menopause. *Fertil Steril*. 2016;106(7):1588–99. <https://doi.org/10.1016/j.fertnstert.2016.09.046>.
- Anderson RA, Amant F, Braat D, et al. ESHRE guideline: female fertility preservation. *Hum Reprod Open*. 2020;2020(4):hoaa052. <https://doi.org/10.1093/hropen/hoaa052>.
- Webber L, Davies M, Anderson R, et al. ESHRE Guideline: management of women with premature ovarian insufficiency. *Hum Reprod*. 2016;31(5):926–37. <https://doi.org/10.1093/humrep/dew027>.
- Lagergren K, Hammar M, Nedstrand E, Bladh M, Sydsjö G. The prevalence of primary ovarian insufficiency in Sweden; a national register study. *BMC Womens Health*. 2018;18(1):175. <https://doi.org/10.1186/s12905-018-0665-2>.
- Løkkegaard E, Jovanovic Z, Heitmann BL, Keiding N, Ottesen B, Pedersen AT. The association between early menopause and risk of ischaemic heart disease: influence of Hormone Therapy. *Maturitas*. 2006;53(2):226–33. <https://doi.org/10.1016/j.maturitas.2005.04.009>.
- Jeon YJ, Choi Y, Shim SH, et al. Vascular endothelial growth factor gene polymorphisms in Korean patients with premature ovarian failure. *Eur J Obstet Gynecol Reprod Biol*. 2011;159(1):138–42. <https://doi.org/10.1016/j.ejogrb.2011.07.007>.
- Baber RJ, Panay N, Fenton A. 2016 IMS Recommendations on women's midlife health and menopause hormone therapy. *Climacteric*. 2016;19(2):109–50. <https://doi.org/10.3109/13697137.2015.1129166>.
- Dragojević Dikić S, Vasiljević M, Jovanović A, et al. Premature ovarian insufficiency - novel hormonal approaches in optimizing fertility. *Gynecol Endocrinol*. 2020;36(2):162–5. <https://doi.org/10.1080/09513590.2019.1640203>.
- Yuanyuan Z, Jiaman W, Yimin Q, Haibo Y, Weiyou Y, Zhuoxin Y. Comparison of Prediction Models based on Risk Factors and Retinal Characteristics Associated with Recurrence One Year after Ischemic Stroke. *J Stroke Cerebrovasc Dis*. 2020;29(4):104581. <https://doi.org/10.1016/j.jstrokecerebrovasdis.2019.104581>.
- Zhuo Y, Wu J, Qu Y, et al. Clinical risk factors associated with recurrence of ischemic stroke within two years: A cohort study. *Medicine (Baltimore)*. 2020;99(26):e20830. <https://doi.org/10.1097/md.00000000000020830>.
- Zhuo YY, Wu JM, Kuang L, et al. The Discriminative Efficacy of Retinal Characteristics on Two Traditional Chinese Syndromes in Association with Ischemic Stroke. *Evid Based Complement Alternat Med*. 2020;2020:6051831. <https://doi.org/10.1155/2020/6051831>.
- Zee CY, Lee JW, Li EQ. Method and device for retinal image analysis. 2014. US Patent 8787638 B2.
- Knudtson MD, Lee KE, Hubbard LD, Wong TY, Klein R, Klein BE. Revised formulas for summarizing retinal vessel diameters. *Curr Eye Res*. 2003;27(3):143–9. <https://doi.org/10.1076/ceyr.27.3.143.16049>.
- Rubanyi GM, Johns A, Kauser K. Effect of estrogen on endothelial function and angiogenesis. *Vascul Pharmacol*. 2002;38(2):89–98. [https://doi.org/10.1016/s0306-3623\(02\)00131-3](https://doi.org/10.1016/s0306-3623(02)00131-3).
- MacLellan RA, Konczyk DJ, Goss JA, Greene AK. Analysis of Follicle-Stimulating Hormone Receptor in Infantile Hemangioma. *Ann Plast Surg*. 2018;80(4 Suppl 4):S211–s3. <https://doi.org/10.1097/sap.00000000000001438>.
- Naftolin F, Friedenthal J, Nachtigall R, Nachtigall L. Cardiovascular health and the menopausal woman: the role of estrogen and when to begin and end hormone treatment. *F1000 Research*. 2019;8:1576.
- Raizada K, Tripathy K. Eales Disease. StatPearls. Treasure Island (FL): StatPearls Publishing Copyright © 2022, StatPearls Publishing LLC.; 2022.
- Harris-Yitzhak M, Harris A, Ben-Refael Z, Zarfati D, Garzoni HJ, Martin BJ. Estrogen-replacement therapy: effects on retrobulbar hemodynamics. *Am J Ophthalmol*. 2000;129(5):623–8. [https://doi.org/10.1016/s0002-9394\(99\)00468-7](https://doi.org/10.1016/s0002-9394(99)00468-7).
- Movsas TZ, Sigler R, Muthusamy A. Elimination of Signaling by the Luteinizing Hormone Receptor Reduces Ocular VEGF and Retinal Vascularization during Mouse Eye Development. *Curr Eye Res*. 2018;43(10):1286–9. <https://doi.org/10.1080/02713683.2018.1495740>.
- Radu A, Pichon C, Camparo P, et al. Expression of follicle-stimulating hormone receptor in tumor blood vessels. *N Engl J Med*. 2010;363(17):1621–30. <https://doi.org/10.1056/NEJMoa1001283>.
- Vannier B, Loosfelt H, Meduri G, Pichon C, Milgrom E. Anti-human FSH receptor monoclonal antibodies: immunochemical and immunocytochemical characterization of the receptor. *Biochemistry*. 1996;35(5):1358–66. <https://doi.org/10.1021/bi952290f>.
- Vu Hai MT, Lescop P, Loosfelt H, Ghinea N. Receptor-mediated transcytosis of follicle-stimulating hormone through the rat testicular microvasculature. *Biol Cell*. 2004;96(2):133–44. <https://doi.org/10.1016/j.biocel.2003.11.008>.
- Straub RH. The complex role of estrogens in inflammation. *Endocr Rev*. 2007;28(5):521–74. <https://doi.org/10.1210/er.2007-0001>.
- Stanhewicz AE, Wenner MM, Stachenfeld NS. Sex differences in endothelial function important to vascular health and overall

- cardiovascular disease risk across the lifespan. *Am J Physiol Heart Circ Physiol*. 2018;315(6):H1569–h88. <https://doi.org/10.1152/ajpheart.00396.2018>.
27. Huang Y, Hu C, Ye H, et al. Inflamm-Aging: A New Mechanism Affecting Premature Ovarian Insufficiency. *J Immunol Res*. 2019;2019:8069898. <https://doi.org/10.1155/2019/8069898>.
 28. Kok HS, van Asselt KM, van der Schouw YT, et al. Heart disease risk determines menopausal age rather than the reverse. *J Am Coll Cardiol*. 2006;47(10):1976–83. <https://doi.org/10.1016/j.jacc.2005.12.066>.
 29. Laven JSE, Visser JA, Uitterlinden AG, Vermeij WP, Hoeyjmakers JHJ. Menopause: Genome stability as new paradigm. *Maturitas*. 2016;92:15–23. <https://doi.org/10.1016/j.maturitas.2016.07.006>.
 30. Kalantaridou SN, Naka KK, Papanikolaou E, et al. Impaired endothelial function in young women with premature ovarian failure: normalization with hormone therapy. *J Clin Endocrinol Metab*. 2004;89(8):3907–13. <https://doi.org/10.1210/jc.2004-0015>.
 31. Rosenbaum JT, Sibley CH, Lin P. Retinal vasculitis. *Curr Opin Rheumatol*. 2016;28(3):228–35. <https://doi.org/10.1097/bor.0000000000000271>.
 32. Paneni F, Diaz Cañestro C, Libby P, Lüscher TF, Camici GG. The Aging Cardiovascular System: Understanding It at the Cellular and Clinical Levels. *J Am Coll Cardiol*. 2017;69(15):1952–67. <https://doi.org/10.1016/j.jacc.2017.01.064>.
 33. de Almeida A, Ribeiro TP, de Medeiros IA. Aging: Molecular Pathways and Implications on the Cardiovascular System. *Oxid Med Cell Longev*. 2017;2017:7941563. <https://doi.org/10.1155/2017/7941563>.
 34. Wellons M. Cardiovascular disease and primary ovarian insufficiency. *Semin Reprod Med*. 2011;29(4):328–41. <https://doi.org/10.1055/s-0031-1280918>.
 35. Christ JP, Gunning MN, Palla G, et al. Estrogen deprivation and cardiovascular disease risk in primary ovarian insufficiency. *Fertil Steril*. 2018;109(4):594–600.e1. <https://doi.org/10.1016/j.fertnstert.2017.11.035>.
 36. Wellons M. Cardiovascular disease and primary ovarian insufficiency. *Seminars in Reproductive Medicine*. 2011;29(4):328–41.
 37. Bozkaya V, Yumusak OH, Ozaksit G, et al. The role of oxidative stress on subclinical atherosclerosis in premature ovarian insufficiency and relationship with carotid intima-media thickness. *Gynecol Endocrinol*. 2020;36(8):687–92. <https://doi.org/10.1080/09513590.2020.1766439>.

Publisher's Note

Springer Nature remains neutral with regard to jurisdictional claims in published maps and institutional affiliations.

Ready to submit your research? Choose BMC and benefit from:

- fast, convenient online submission
- thorough peer review by experienced researchers in your field
- rapid publication on acceptance
- support for research data, including large and complex data types
- gold Open Access which fosters wider collaboration and increased citations
- maximum visibility for your research: over 100M website views per year

At BMC, research is always in progress.

Learn more biomedcentral.com/submissions

